Eur J Vasc Endovasc Surg **32**, 570–576 (2006)
doi:10.1016/j.ejvs.2006.04.002, available online at http://www.sciencedirect.com on ScienceDirect

External Venous Valve Plasty (EVVP) in Patients with Primary Chronic Venous Insufficiency (PCVI)

A. Rosales,[1*] C.E. Slagsvold,[2] A.J. Kroese,[1] E. Stranden,[2] Ø. Risum[1] and J.J. Jørgensen[1]

[1]*Oslo Centre for Vascular Surgery, and* [2]*Department of Vascular Diagnosis and Research, Aker University Hospital, Oslo, Norway*

Objectives. *To evaluate the patency of EVVP and its effect in symptom relief, ulcer healing and ulcer-free period in patients with PCVI.*
Methods. *Between 1993 and 2004, 1800 patients with CVI were evaluated and seventeen with PCVI were selected for EVVP. They were all investigated with ambulatory venous pressure measurement (AVP), colour duplex ultrasound (CDU), ascending venography and descending video venography. The CEAP classification was used to group the patients. Six patients were C4, four C5 and seven C6. All had deep reflux and high levels of AVP.*
Results. *All procedures were technically successful. The ulcer healing rate was 4/7 (57%) within 3 months. All C4 patients experienced symptom improvement postoperatively and had a median recurrence free period of 72 (range 60–122) months. The C5 group had an median ulcer free period of 61 months (12–72) and the C6 of median 48 (12–72) months. Single valve plasties (4) reached a median competence period of 48 months (12–72), 12 multiple valve plasties at the same level show a median 78 months (63–122) and 10 multilevel repairs median 54 months (12–96). Multiple valve plasties at the same level (multi-station plasties) performed on the C4 group seemed to yield the longest durability with a median of 103 months (84–122).*
Conclusion. *EVVP with an ulcer healing rate of 57% and satisfactory symptom improvement seems to be an alternative of surgical treatment for selected patients with PCVI. The durability of this technique seems to be related to clinical severity and the multiplicity of repairs.*

Keywords: Venous insufficiency; Valve plasty; Clinical and functional outcome; Venous pressure measurements; Venous reflux.

Introduction

Patients with chronic venous insufficiency (CVI) and leg ulceration constitute a serious medical and social problem. The prevalence of venous leg ulcers is reported to be 0.1 to 1.0.[1–3] The total direct annual cost of treatment of venous leg ulcers in Sweden has been estimated at 73 million Euro based on a prevalence of 0.3 percent and 45 percent venous ulcers.[4] In the UK the cost is between 400–600 million pounds per year.[5]

Patients may suffer *primary* venous incompetence of unknown cause in which familial predisposition plays a role in the aetiology of their disease. The defective venous valves in this group of patients often are amenable to surgical repair. In *secondary* venous incompetence valve leaflets have often been damaged by an episode of deep venous thrombo-embolism (DVT), making surgical repair impossible. In the majority of cases adequate compression and local treatment of leg ulceration has been the main stay of *symptomatic* treatment. A great challenge has been finding an effective *causal* therapy, i.e. repairing incompetent valves that are causing reflux. Reflux is one of the main pathophysiological factors in CVI that can be surgically corrected.

Superficial and perforator reflux is abolished by excision or ligation of the affected veins, while deep venous reflux represents a major challenge since it requires either repairing or replacing the valve structure for it to regain competence. Since the introduction of the open valveplasty in 1968 by Kistner, a series of antireflux procedures have been described, including the external venous valve plasty (EVVP).[6–7] In patients with PCVI it is possible to find valves amenable to repair with this particular technique.

*Corresponding author. Antonio Rosales MD, Oslo Centre for Vascular Surgery, Aker University Hospital, N-0514 Oslo, Norway.
E-mail address: antonio.rosales@aker-sykehus.no

1078–5884/000570 + 07 $35.00/0

The aim of this study is to evaluate the effect of EVVP on patient symptoms, ulcer healing rate, ulcer-free period and period of competence following repair in patients with severe PCVI.

Material and Methods

Between 1993 and 2004, 1800 patients with CVI were referred for consideration of reconstructive deep venous surgery (RDVS). They were initially evaluated at our vein clinic and vascular laboratory by colour duplex ultrasound (CDU) and ambulatory venous pressure measurement (AVP). PCVI was diagnosed in only one third of the patients and the rest had a secondary CVI. Among those with PCVI about half had superficial and perforator vein incompetence with a normal deep venous system. Forty percent had a combined deep, superficial and perforator incompetence that responded to treatment without reconstructive deep venous surgery (RDVS). From the remaining 10% of patients with PCVI seventeen were selected for EVVP. All these patients had a long history of disabling venous insufficiency with skin changes and/or ulceration.

The median age of patients was 52 years (range 28–75) with a male predominance (M: 11, F: 6). This selected group was further investigated with ascending venography and descending video venography.[8] 5 patients were considered to be grade III and 12 patients grade IV according to the Kistner classification of reflux. The CEAP classification was used to group the patients (Table 1).[9]

Patients presenting with concomitant superficial and/or perforator insufficiency were first treated with partial stripping of the long saphenous vein, resection of the short saphenous vein and/or conventional perforator ligation. Patients were treated for a period of six months with class 2 compression stockings before considering (RDVS). Failure to heal an ulcer (11) or improve symptoms of venous disease (6) after this regimen was an indication to perform RDVS. Impaired venous-muscle pump function due to ankle arthrodesis and calf muscle atrophy, constituted a major contraindication for treatment by RDVS.

Patients were followed-up at 3 months and then every 6 months by clinical examination, CDU and AVP.

Investigations

Ambulatory venous pressure (AVP) measurement is still considered the reference standard in the assessment of global reflux, function of the veno-muscular pump and the severity of venous hypertension. A 21-gauge ''butterfly'' needle was inserted into a vein in the leg and connected to a pressure transducer, a pressure monitor and a recorder (Fig. 1). Canulation of dorsal foot veins should be avoided due to the possibility of falsely normal values caused by functioning valves at the ankle level.[10] At upright position the patients were supported by a frame. At rest, the distance between the heart level and the canulation site determines the recorded venous pressure. The patients then performed a standardised ''walking on the spot'' exercise. The mean venous pressure recorded when the curve flattens at the end of this exercise indicates the ambulatory venous pressure (AVP). Normally the pressure drops to below 30 mmHg. The measurement is then repeated after selective occlusion of the superficial veins. A 30 cm wide pneumatic tourniquet is placed around the thigh and inflated to 60 mmHg to occlude the long saphenous and other superficial thigh veins. The short saphenous vein may be occluded with a rubber tourniquet. By selectively occluding the superficial segments it is possible to identify the incompetent venous system (i.e. either the great or small superficial saphenous veins or the deep system) (Fig. 1).

AVP measurement provides the following information: pressure drop during exercise, ambulatory pressure and recovery time, which is the time taken from cessation of the step test until the resting pressure level is reached.

Colour duplex ultrasound (CDU) was use to evaluate axial reflux in the different anatomical segments of each venous system. The examination was performed with the patient standing, weight-bearing primarily on the contralateral limb. A 12 cm wide pneumatic cuff is placed distally to the segment to be examined, and connected to a venous compression unit which

Table 1. Comparison of groups C4 (skin changes), C5 (healed ulcer) and C6 (manifest ulcer) with regard to pre-operative, functional findings and number of EVVP performed. The material according to the CEAP classification showing deep insufficiency and the number of reconstructions performed in the different clinical groups

Clinical stage (CEAP)	N	Deep reflux	AVP (mmHg)	Single plasty	Multistation plasty	Multilevel plasty
C4	6	6	72	2	4	2
C5	4	4	80	1	3	2
C6	7	7	85	1	5	6

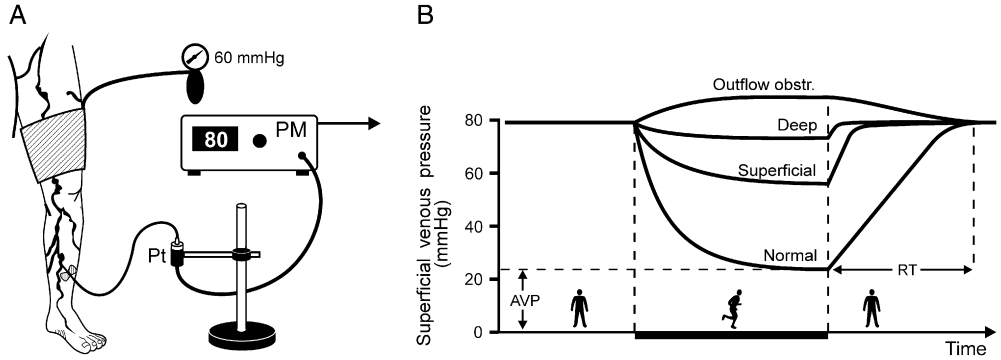

Fig. 1. A: Vein pressure recording setup. B: Typical superficial vein pressure curves at rest and during walking in subjects with no venous insufficiency (Normal), superficial- and deep venous insufficiency, and venous outflow obstruction. Note that dorsal foot vein is not cannulated.[10] Pt: Pressure transducer, PM: Pressure monitor, AVP: Ambulatory venous pressure.

enables very fast (<0.2 s) inflation and deflation (VenoPulse, E. Stranden). The inflation pressure is adjustable, and set at 150 mmHg. The venous compression unit ensures a standardized repeatable venous reflux procedure (inflation of the cuff, sustained for 3 s and then deflated), which in our opinion to a larger degree mimics venous reflux than the commonly used Valsalva manoeuvre. The latter method may miss distal venous incompetence which is masked by a competent proximal valve, and in some elderly patients the effort applied to the manoeuvre is reduced because of fear of incontinence.

5 and 10 MHz ultrasound probes were used to detect venous reflux (GE Vingmed System V, Horten, Norway). A valve closure time >0.5 s was defined as pathological.[11] Although there are recent reports in the literature suggesting that the peak reflux velocity correlates better with the severity of venous insufficiency, valve closure time is more widely used.[12]

Descending video venography is a dynamic imaging method of the venous valve leaflets that may be amenable to repair allowing classification of the severity of axial reflux. Contrast medium is injected through a femoral puncture which allows an obstruction in the ilio-caval segment can be excluded. The patient is then tilted 60 degrees, head upward, and dye injected during a Valsalva manoeuvre. The dye column is followed distally until it stops or the Valsalva manoeuvre is completed (Fig. 2)[8] and graded into 4 categories described by Kistner[13]: Grade I proximally in the thigh, grade II above the knee, grade III below the knee, and grade IV to the ankle.

EVVP – surgical technique

The feasibility of valve repair was established by preoperative CDU and descending video venography and in some cases with intra-operative angioscopy. A conventional approach was applied in the groin through a longitudinal incision and a posterior approach in the popliteal fossa by using an S-shape incision. Magnifying loupes were routinely used. The valve site and the commissural sites of the leaflets were identified by careful adventitial dissection. At this point angioscopy can be helpful in identifying the valve commissures, and testing valve function (Fig. 3).[8,14,15] A continuous suture line of 5–7 stitches with polypropylene 7–0 was started at the cranial end of the valve to tighten the leaflets. This procedure was performed at the site of both commissures. The repaired valve was then tested either by the "strip-test" or angioscopy (Figs. 3 and 4).

A 2.8 mm angioscope with a flushing channel connected to a pump and introduced through a side branch was used in the performance of EVVP in 5 patients. The valve was first tested for incompetence by flushing with saline solution. Closure of the repaired valve when injecting saline at a flow rate of 30 ml/min proves competence.

Single valvuloplasties can be performed at the femoral or popliteal level. *Multilevel* plasties can be performed at both levels in the same extremity. The term *multistation* plasties refers to repairing more than one valve at the femoral level (common, superficial and deep femoral vein).

Anticoagulation with low molecular weight heparin (dalteparin) was administered to all patients before, during and for three months after surgery. After that anticoagulants and platelet inhibitors were discontinued. This was a prophylactic measure since thrombosis after EVVP is reported by other authors.[19]

All patients treated by EVVP are advised to continue using elastic stockings, if possible of a lower compression class, for the rest of their lives. The great majority of patients complied with this advice because

Fig. 2. A sequence of 6 pictures from the descending video venography demonstrating venous reflux down to knee level (grade II). This exemplifies the advantage of video recording where the contrast medium can be followed dynamically at the desired speed to study venous valve function.

of the duration of symptoms and were motivated to help prevent recurrence of their symptoms. Supplementary elastic stockings will reduce some of the strain in the venous system and may influence the durability of EVVP.

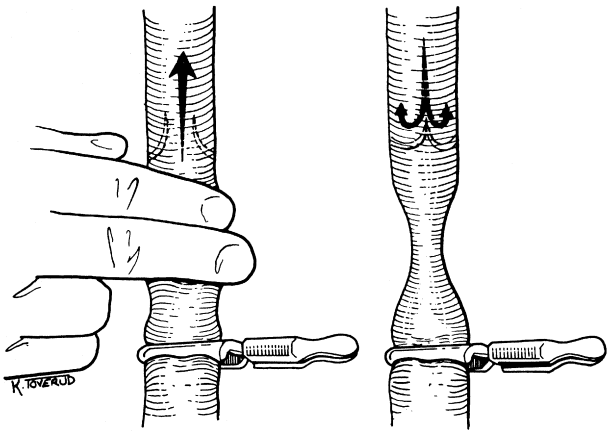

Fig. 3. "Strip test" to confirm valve patency.

Statistical methods

Our strategy in the study was pragmatic. For discrete variables we used the Students t-test and for continuous variables the Mantel-Henzel test. For comparison of the different results we used Kaplan-Meier survival curves. We were aware of the lack of power in the study. All data are presented as median and range.

Results

All procedures were performed by the same surgeon and proved to be technically successful according to the strip test or angioscopoic findings. *Multistation* repairs were performed in twelve patients: double repair in eight, triple plasties in four. *Multilevel* repairs were done in ten patients. In eight patients the popliteal vein valve was repaired alone or in combination with femoral repair.

The clinical and haemodynamic endpoints were ulcer or symptom recurrence, reflux and/or a high level of

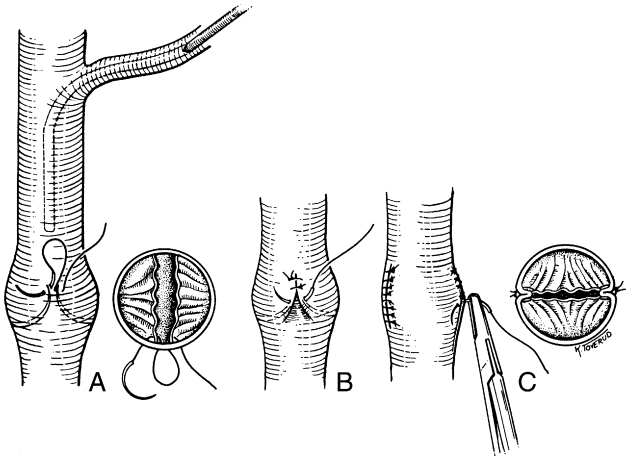

Fig. 4. The surgical technique of external venous valve plasty assisted by angioscopy: a view of incompetent valve cusps and the first external suture placed in a commisure (a), external sutures in both commisures (b) and the finished valve repair (c).

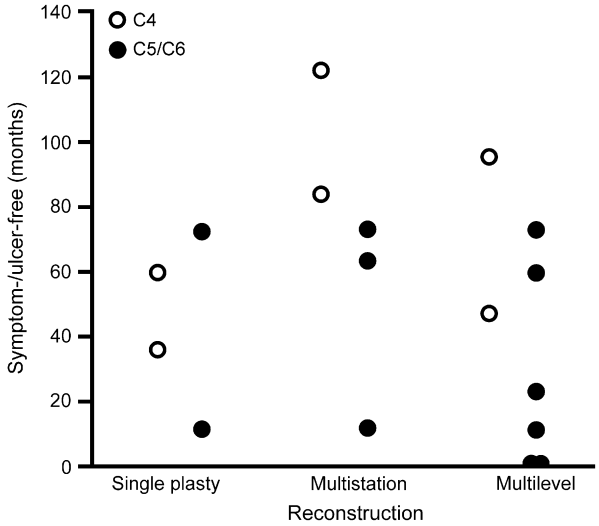

Fig. 5. Comparison of clinical outcome (symptoms-/ulcer free months) and number/level of reconstruction. There was no statistical significant difference between groups.

AVP. The clinical recurrence was related to reflux shown by CDU and high AVP in all cases. At 3 months follow-up all except one patient showed competent functioning valve plasties. The total follow-up period was 60 months (range 3–122). Single plasties had a patency of 48 months (12–72), multistation plasties 72 months (63–122) and multilevel repairs 36 months (12–96).

The healing ulcer rate was 4/7 (57%) within 3 months. All C4 patients (skin changes) experienced symptom relief postoperatively and had a recurrence free period (symptoms) of median 72 (60–122) months. The ulcer-free period in the C5 group (chronically recurrent ulcer, but presently healed) and the C6 group (manifest ulcer) was 61 months (12–72) and 48 months (12–72), respectively (Fig. 5).

Postoperatively, the AVP reduction was greatest in the C6 group, median 35 mmHg (0–65) (Fig. 6). This reduction was maintained through the follow-up period until the valve plasty became incompetent.

Three patients did not experience any clinical improvement despite a patent EVVP at the follow-up (Fig. 7). This was probably due to an incompetent calf muscle-pump.

Our results did not reach statistical significance, largely due to the small size of the study group.

Discussion

The aim of our study was to evaluate the clinical and haemodynamic effects of EVVP, as well as its durability in patients with PCVI. After treating concomitant superficial and/or perforator insufficiency; we added an observation period of six months with optimal compression therapy enabling us to evaluate the results of the EVVP itself.

The recurrence-free period achieved in the C4 group was longer than the recurrence- free period in the C5 and C6 groups. Multistation repairs were performed in all groups, most frequently in the C4 group, and seemed to yield the longest durability (Fig. 5). The ulcer free period in C5 and C6 was longer among those

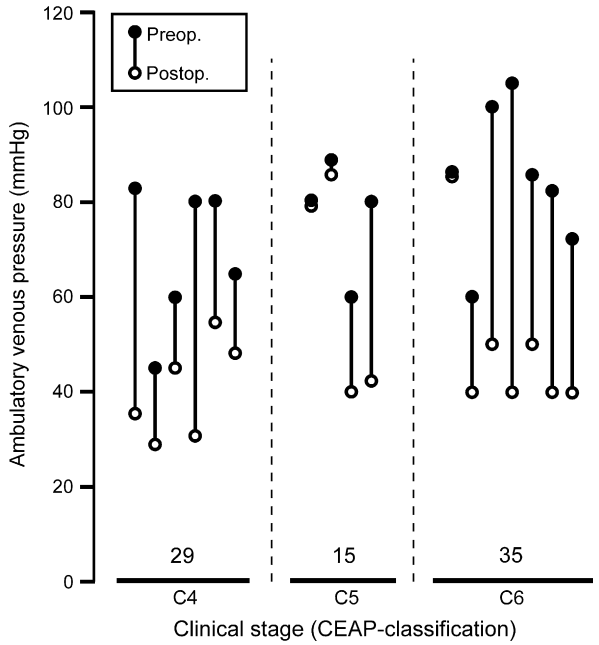

Fig. 6. The reduction in ambulatory venous pressure accomplished by external venous valve plasty in the CEAP groups 4, 5 and 6, respectively. The numbers refer to the median reduction in ambulatory venous pressure.

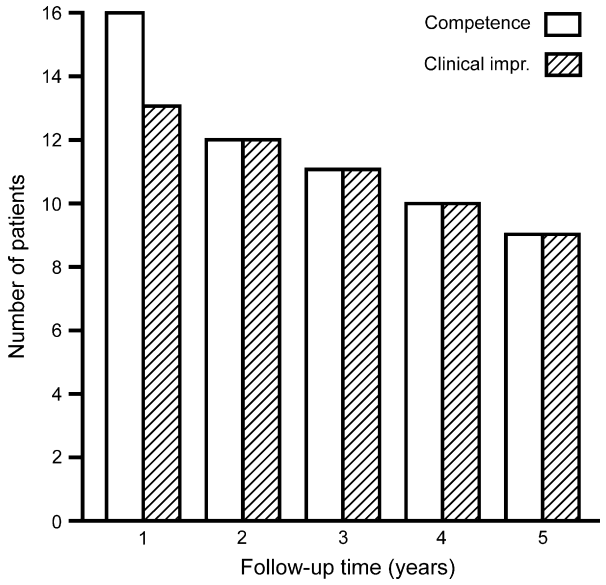

Fig. 7. Patency and clinical improvement were directly related in the follow-up period, except for three patients that did not experience clinical improvement despite a competent external venous valve plasty.

with multistation repairs. Even though statistical significance was not achieved probably due to the small sample, our results suggested that multistation repairs have more durable competence compared to single plasties, regardless of the clinical stage. The C4 group had better overall results, irrespective of the number of reconstructions. There was a direct correlation between symptom/ulcer recurrence and recurrence of reflux/high AVP during the follow-up period (Fig. 7).

The indication for RDVS in other reports was mainly C5 and C6 patients.[16] We have extended the indication to C4 patients with severe symptoms and a high AVP (>60 mmHg), since we may be able to avoid the development of an ulcer by intervening at this stage.

Our results compare favourably with the literature in this field. Raju *et al.*[17] reported cumulative competence period and ulcer-free interval of 63% after 30 months with a similar technique.[17] Tripathi *et al.*[16] showed an ulcer healing rate of 50% and a competence at the valve stations of 31% after 2 years.[16] Our 3 and 5 year competency after EVVP was 64% and 52%, respectively. These results provided an ulcer-free interval to C5 patients of median 61 months and C6 patients of median 48 months. C4 patients had a symptom recurrence-free interval of median 72 months. The clinical improvement and ulcer healing rate after this procedure seems to be better than that provided by traditional compression therapy.

Some investigators advocate the internal repair.[18–20] We preferred the EVVP, especially because it does not require a venotomy with the potential hazard of damaging the valve cusps. In addition, several repairs can be performed during the same operation because EVVP is less time consuming.

Among patients with secondary CVI there is a limited group that has a combination of destroyed valves and incompetent but otherwise undamaged valves, where EVVP still is possible. But the largest group with valves amenable to EVVP is definitely among those with PCVI. The number of these patients in our group was rather small, perhaps for several reasons. These were patients with a complicated history and generally there was a favourable response to the initial superficial/perforator surgery and compression therapy.

In our opinion the measurement of AVP is still the reference standard when evaluating the overall venous function in the lower limb. The use of photoplethysmography instead of AVP has been suggested because it is a non-invasive test.[21] However, we prefer measuring AVP since this parameter is *directly* related to the patients' symptoms.

We used AVP pre-operatively as well as during the follow-up period. Combining the information from CDU and descending video-venography was an effective way to asses the degree of reflux and to identify incompetent valves which could be repaired. EVVP requires meticulous adventitial dissection and the use of magnifying loupes is necessary in order to identify the valve cusps. The use of an angioscope can make this part of the procedure easier.

The relatively small size of our group of patients treated by EVVP prevents us from drawing definite conclusions about the best method of valve repair. We have found that external venous valve plasty is an effective way of treating patients with primary chronic venous insufficiency. Careful selection of patients based on clinical findings and an extensive haemodynamic and imaging work-up is mandatory.

References

1 Nelzen O, Bergqvist D, Lindhagen A. The prevalence of chronic lower-limb ulceration has been underestimated: results of a validated population questionnaire. *Br J Surg* 1996;**83**(2):255–258.
2 Ruckley CV. Socioeconomic impact of chronic venous insufficiency and leg ulcers. *Angiology* 1997 Jan;**48**(1):67–69.
3 O'Brien JF. Prevalence and aetiology of leg ulcers in Ireland. *Ir J Med Sci.* 2000 Apr–Jun;**169**(2):110–112.
4 Tennvall GR, Andersson K. Treatment of venous leg ulcers can be better and cheaper. Annual costs calculation based on an inquirystudy. *Lakartidningen* 2004;**101**(17):1506–1523.
5 Simka M, Majewski E. The social and economic burden of venous leg ulcers: focus on the role of micronized purified flavonoid fraction adjuvant therapy. *Am J Clin Dermatol* 2003;**4**(8):573–581.
6 Raju S, Hardy JD. Technical options in venous valve reconstruction. *Am J Surg* 1997;**173**(4):301–307.

7 Kistner RL. Surgical techniques of external venous valve repair. The Straub Medical Research and Education Foundation. *Straub Found Proc* 1990;**55**(2):15–16.
8 Kroese AJ, Rosales A, Flørenes T, Stiris M, Stranden E. Video venography and angioscopy for reconstructive venous surgery. In: Greenhalgh RM, ed. *Vascular imaging for surgeons*. W.B. Saunders Company Ltd; 1995:513–521.
9 Beebe HG, Bergan JJ, Bergqvist D, Eklof B, Eriksson I, Goldman MP *et al*. Classification and grading of chronic venous disease in the lower limbs–a consensus statement. Organized by Straub Foundation with the cooperation of the American Venous Forum at the 6th annual meeting, February 22–25, 1994, Maui, Hawaii. *Vasa* 1995;**24**(4):313–318.
10 Stranden E, Øgreid P, Seem E. Venous pressure gradients in controls and in patients with chronic venous disease. *Phlebology* 1986;**1**:47–50.
11 Van Bemmelen PS, Bedford G, Beach K, Strandness DE. Quantitative segmental evaluation of venous valvular reflux with duplex ultrasound scanning. *J Vasc Surg* 1989;**10**(4):425–431.
12 Neglen P, Egger III JF, Olivier J, Raju S. Hemodynamic and clinical impact of ultrasound-derived venous reflux parameters. *J Vasc Surg* 2004;**40**(2):303–310.
13 Kistner RL, Ferris EB, Randhawa G, Kamida C. A method of performing descending venography. *J Vasc Surg* 1986;**4**(5): 464–468.
14 Hoshino S, Satakawa H, Iwaya F, Igari T, Ono T, Takase S. [External valvuloplasty under preoperative angioscopic control]. *Phlebologie* 1993;**46**(3):521–529.
15 Welch HJ, McLaughlin RL, O'Donnell Jr TF. Femoral vein valvuloplasty: intraoperative angioscopic evaluation and hemodynamic improvement. *J Vasc Surg* 1992;**16**(5):694–700.
16 Tripathi R, Sieunarine K, Abbas M, Durrani N. Deep venous valve reconstruction for non-healing leg ulcers: techniques and results. *ANZ J Surg* 2004;**74**(1–2):34–39.
17 Raju S, Berry MA, Neglen P. Transcommissural valvuloplasty: technique and results. *J Vasc Surg* 2000;**32**(5):969–976.
18 Masuda EM, Kistner RL. Long-term results of venous valve reconstruction: a four- to twenty-one-year follow-up. *J Vasc Surg* 1994;**19**(3):391–403.
19 Perrin M. Reconstructive surgery for deep venous reflux: a report on 144 cases. *Cardiovasc Surg* 2000;**8**(4):246–255.
20 Raju S, Fredericks RK, Neglen PN, Bass JD. Durability of venous valve reconstruction techniques for "primary" and postthrombotic reflux. *J Vasc Surg* 1996;**23**(2):357–366.
21 Fronek A, Kim R, Curran B. Non-invasively determined ambulatory venous pressure. *Vasc Med* 2000;**5**(4):213–216.

Accepted 2 April 2006
Available online 21 August 2006

Eur J Vasc Endovasc Surg (2008) **36**, 466—472

Venous Valve Reconstruction in Patients with Secondary Chronic Venous Insufficiency

A. Rosales*, J.J. Jørgensen, C.E. Slagsvold, E. Stranden, Ø. Risum, A.J. Kroese

Oslo Vascular Centre, Aker University Hospital and Faculty of Medicine, University of Oslo, Norway

Submitted 15 October 2007; accepted 8 June 2008
Available online 3 August 2008

KEYWORDS
Chronic venous insufficiency;
Venous valve reconstruction;
Venous reflux

Abstract *Objectives:* To evaluate the durability of venous valve reconstruction (VVR) and its benefits in terms of symptom improvement, ulcer healing and symptom/ulcer recurrence among patients with secondary chronic venous insufficiency (SCVI) in whom superficial venous surgery and compression treatment had failed.
Methods: During a ten year period (1993—2004) 1800 patients with chronic venous insufficiency (CVI) were evaluated by colour duplex ultrasound (CDU) and ambulatory venous pressure measurement (AVP). Approximately two thirds of patients had SCVI. Initial treatment consisted of compression therapy for a 6 month period. In addition, superficial vein and perforator surgery was performed in those presenting with reflux in these venous systems. 121 patients who did not improve with this treatment were investigated by ascending venography, descending video venography, air plethysmography and measurement of post-ischaemic venous pressure gradient. Thirty two cases having venous reflux without obstruction were selected for VVR.
Results: The ulcer healing rate within three months was 68% (13/19 patients). VVR resulted in valvular competence and a clinical success rate of 47% and 40% after 3 and 7 years respectively. In 8/13 (54%) of patients with a healed leg ulcer, a median post-operative AVP reduction of 33 mm Hg (range 20—38) was recorded. The durability of clinical success was numerically longer in patients with haemodynamic improvement ($n = 10$) median 24 months (12—108), when compared with that in those *without* haemodynamic improvement ($n = 22$) median 18 months (6—108). Popliteal vein reconstruction was part of the VVR procedure in all patients with haemodynamic improvement (post-op. AVP reduction $\geq$20 mm Hg). VVR at the popliteal level alone or combined with inguinal reconstruction seemed to be the one significant factor associated with haemodynamic improvement ($P = 0.014$, Chi squared).

* Corresponding author. A. Rosales, Department of Vascular Surgery, Oslo Vascular Centre, Aker University Hospital, N-0514 Oslo, Norway. Tel.: +47 2289 4000; fax: +47 2222 5648.
E-mail address: anto-r@online.no (A. Rosales).

doi:10.1016/j.ejvs.2008.06.015

Conclusion: VVR may lead to ulcer healing, but when performed at the popliteal level, haemodynamic improvement can be obtained along with a longer recurrence-free period (durability). VVR should be considered in the treatment of patients with SCVI who do not respond to superficial venous surgery and compression treatment.

Introduction

The incidence of deep venous thrombosis (DVT) remains as high as 160/100 000/per year, despite the increasing use of prophylaxis with low molecular weight heparins (LMWH) during hospital treatment.[1] Long-term follow-up studies have shown that as many as 40% of patients suffering an episode of DVT will develop secondary chronic venous insufficiency (SCVI), by which we mean venous disease resulting in skin changes and leg ulceration.[2,3] Venous valve destruction occurs during both the acute inflammatory phase of thrombosis and during the reabsorption the thrombi which in turn may lead to venous reflux or outflow obstruction. The serious clinical consequences of this process are leg ulceration or venous claudication experienced by at least 15% of patients with SCVI.[4] The main stay of the treatment for patients with SCVI is compression therapy combined with anticoagulation in patients experiencing recurrent thrombotic episodes due to hereditary thrombophilia.[5–9]

Venous valve reconstruction (VVR) has had a limited role in the treatment of this group of patients. This is partly due to the need for accurate pre-operative haemodynamic evaluation, clear indications for operation and demanding operative technique.[10–12] In addition, chronic venous insufficiency is a chronic disease under-prioritised in most surgical units and the reported results do not seem to have had the necessary impact in the vascular surgery community.

The aim of our study was to evaluate the durability of VVR and its benefits in terms of symptom improvement, ulcer healing and symptom or ulcer recurrence among patients with SCVI in whom conventional treatment had failed.

Patients and Methods

Between 1993 and 2004, 1800 patients with chronic venous insufficiency (CVI) resulting in skin changes or leg ulcers were evaluated in our vein clinic with colour duplex ultrasound (CDU) and ambulatory venous pressure measurement (AVP). In approximately two thirds of patients SCVI was diagnosed on the basis of the clinical history and CDU findings. These patients were treated by conservative compression therapy for six months. In addition, superficial and perforator surgery was performed in those with venous incompetence affecting these vessels. A group of 121 patients did not improve with this treatment and was further investigated with ascending venography, descending video venography, air plethysmography and measurement of post-ischaemic venous pressure gradient (modified Raju's test).[13] Fifty-two cases with reflux and/or outflow obstruction were identified as amenable for reconstructive deep venous surgery (RDVS). Those patients with venous reflux who did not have venous outflow obstruction ($n = 32$) constitute the patients included in the present study.

Inclusion criteria:
- Symptomatic SCVI patients (C4-C6) in whom compression therapy for at least 6 months, combined with superficial venous and perforator surgery where appropriate, failed to obtain clinical improvement.
- SCVI patients presenting evidence of venous reflux without outflow obstruction.
- Age $\leq$ 70 years

Exclusion criteria:
- SCVI patients with evidence of venous outflow obstruction
- Ankle arthrodesis with secondary muscle atrophy
- Age $>$ 70 years
- General contraindications to surgery

Patients were examined clinically by a surgeon experienced in the management of venous disease and the appropriate CEAP classification assigned to each patient.[14]

Investigations

Ambulatory venous pressure (AVP) measurement was used to assess global reflux, function of the veno-muscular pump and the severity of venous hypertension. AVP provides information about a pressure drop with ambulation (a measure of the venous pump function), ambulatory pressure and recovery time.

Colour duplex ultrasound (CDU) was used to evaluate axial reflux in the different anatomical segments of each venous system.

Descending video venography is a dynamic imaging of the venous valve leaflets that may be amenable to repair and allows classifying the severity of the axial reflux according to Kistner: Grade I proximally in the thigh, Grade II above the knee, Grade III below the knee, Grade IV to the ankle.[15] *These methods have been described in detail previously.*[16]

To evaluate the haemodynamic significance of a post-thrombotic vein occlusion two additional investigations were performed:

Venous occlusion plethysmography (VOP) is performed to exclude persistent venous outflow obstruction by using an air plethysmograph (MacroLab, E. Stranden). In the recumbent position venous occlusion and recording cuffs were applied proximally to the patella and at the calf, respectively. An occlusive cuff pressure of 50 mm Hg was maintained for one minute. This permits uninhibited arterial flow into the limb, while the venous outflow is

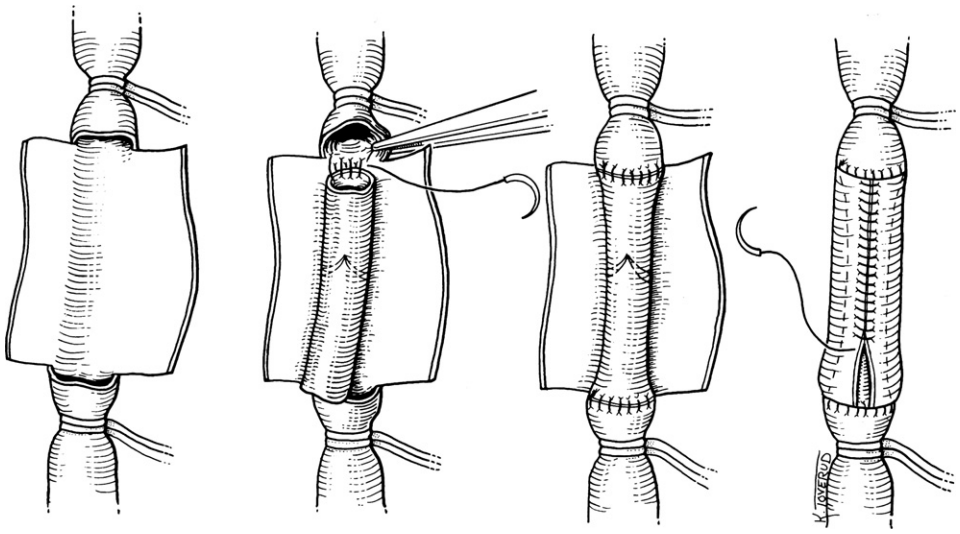

Figure 1 The venous segment containing a competent valve is transplanted as an interposition by using in-lay technique. The native vessel is ''wrapped'' around as reinforcement. Diameter discrepancy, thickening and fibrosis of the native vessel pose the major technical challenges in this procedure.

compromised, resulting in an increased leg volume. On decompression of the thigh cuff the leg volume decreases rapidly when the venous outflow is normal. In the presence of a functional venous obstruction the leg volume will decrease slowly. Normally on decompression the empty velocity is $\geq$25 mm/second.

Venous pressure gradient is obtained by comparing venous pressure measurements before and after a reactive hyperaemia test of the lower extremity. An inflatable tourniquet is applied to the thigh, and venous pressure is recorded in a superficial leg vein. With the patient in supine position a basal measurement is made. The thigh tourniquet is then inflated to 300 mm Hg pressure and maintained for 3 minutes. After releasing the tourniquet, reactive hyperaemia increases venous outflow. A normal outflow resistance ensures a concomitant venous pressure increase under 8 mm Hg. Levels above 8 mm Hg will suggest an outflow obstruction.[13]

Surgical Technique

Postthrombotic changes leading to reflux do not develop in a fixed pattern. The use of different surgical techniques in the one patient may be necessary adequately to deal with all incompetent deep veins.

Autotransplantation

The main objective of VVR is to abolish reflux in both femoral and/or popliteal veins. A vein diameter $<$5 mm and signs of fibrosis/trabecula diagnosed by CDU and/or venography are our criteria to rule out those veins not fit for auto-transplant. A competent valve is identified preoperatively with CDU in the axillary or the saphenous veins. A 6—8 cm long vein segment containing a functioning valve is harvested. The valve is tested by injecting saline solution. Sometimes the axillary vein valve is found incompetent after it has been harvested and a bench external plasty must be performed. In the groin the femoral vein is exposed through a longitudinal incision, whereas in the popliteal fossa we use a posterior approach and an S-shape incision. The venous segment containing a competent valve is then implanted as an interposition by using in-lay suturing technique (Fig. 1). This involves two end-to-end anastomoses with 6-0 polypropylene. We use a running suture, interlocking every other suture, to avoid a ''purse-string'' effect. The cranial anastomosis is performed first. The ''strip test'' confirms the competence of the transplant Fig. 2. The native vessel is ''wrapped'' around as reinforcement without compromising the valve function. Diameter discrepancy, thickening and fibrosis of the native vessel pose the major technical challenges in this procedure. The donor sites chosen were the saphenous (contralateral or ipsilateral) and axillary veins. The great and small saphenous veins were used as the

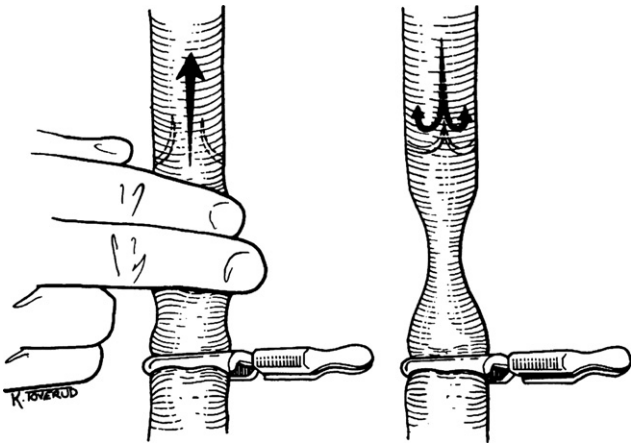

Figure 2 ''Strip test'' is performed to confirm the competency of the procedures.

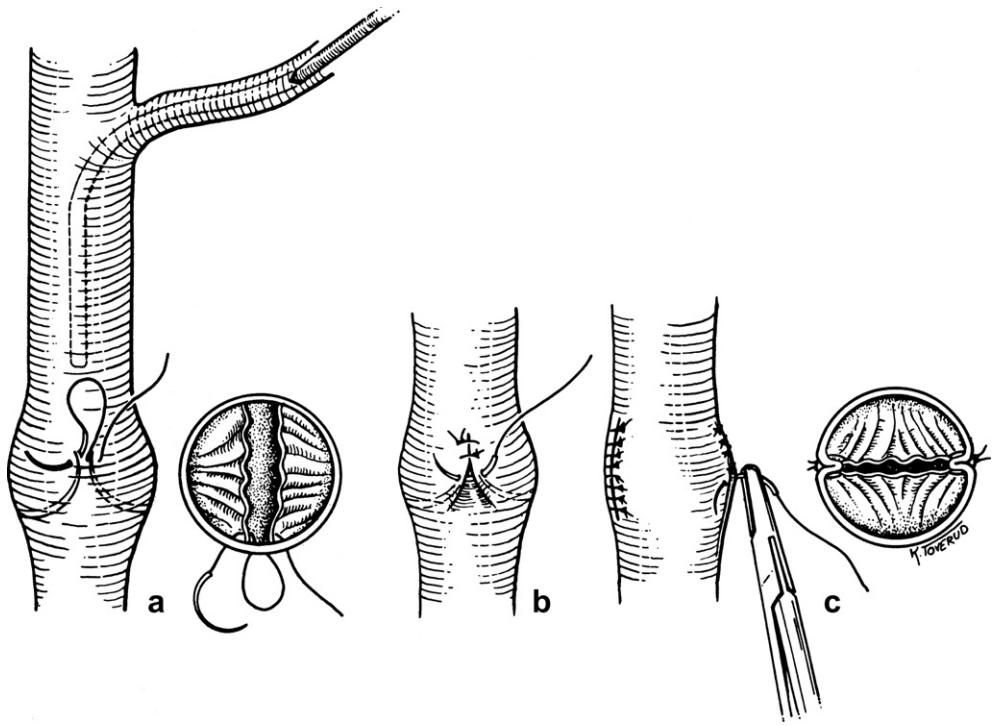

Figure 3 The surgical technique of external venous valve plasty assisted by angioscopy: a view of incompetent valve cusps and the first external suture placed in a commissure (a), external sutures in both commissures (b) and the finished valve repair.

donor site in 23 and 3 transplant cases, respectively. In six cases the axillary vein was used as donor. Autotransplantation to the popliteal level was performed in 24 patients.

External venous valve plasty

In some SCVI patients descending video-venography and CDU show incompetent but not damaged venous valves amenable to repair. In these cases we use the external venous valve plasty technique. Details of the technique are previously described.[11,16] (Fig. 3).

Transposition

Occasionally a vein transposition procedure was performed. This involves taking an incompetent post-thrombotic vein segment and anastomosing it end-to-side, distally to a competent valve, for example the superficial femoral vein anastomosed distally to a competent valve in the great saphenous vein.[11,16] (Fig. 4).

All procedures were performed by the same surgical team and were tested intra-operatively using a retrograde flow test (strip-test) in order to confirm that competence had been restored to the operated veins.

Anticoagulation

Pre-and intra- operative full anticoagulation is used with LMWH and continued for six months postoperatively. We use dalteparin 200 IU/kg body weight/daily administered subcutaneously. Those patients with a hereditary

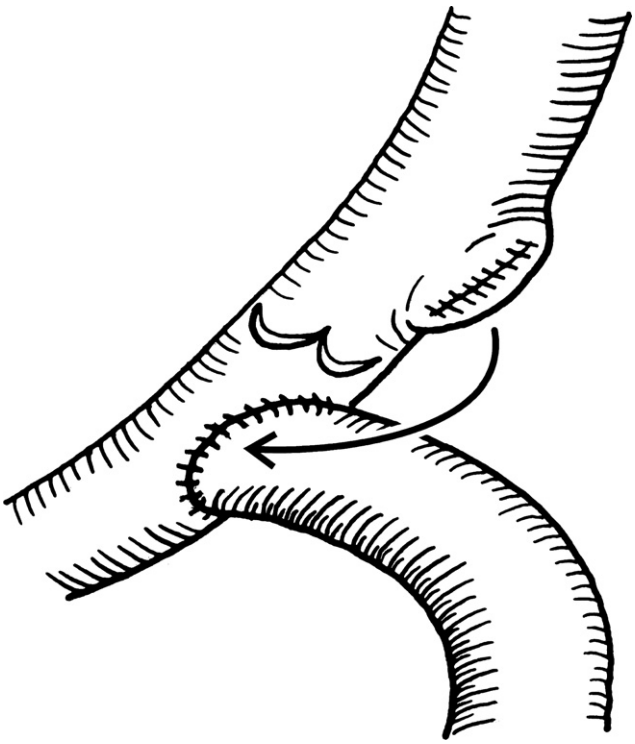

Figure 4 Transposition involves taking a refluxive post-thrombotic vein segment and anastomosing it end-to-side, distally to a competent valve.

Table 1 Thrombophilias detected in this series of SCVI patients (14/32)

Haematological defect	N
Protein C deficiency	4
Protein S deficiency	4
Activated protein C resistance	3
Anti-thrombin	2
Homocysteinuria	1

thrombophilia have been advised to continue life-long anticoagulation with warfarin.[6]

Follow-up and definitions

Patients were followed-up at three months and thereafter every 6 months by clinical examination, CDU and AVP. The median follow-up period was 24 months (6—108). *Clinical success* was defined as symptom relief and/or ulcer healing. The patient's ability to go back to work and normal activity after VVR and the subjective experience of symptom improvement were the two parameters used to define *symptom relief*. *Haemodynamic improvement* was defined as a post-operative AVP reduction of ≥20 mm Hg. *The clinical endpoints* were ulcer- and/or symptom recurrence. The number of months that a reconstruction remained competent verified with CDU is referred to as *durability*.

Statistics

We have chosen a follow-up study of patients with SVCI submitted to VVR describing the incidence of clinical success and haemodynamic improvement of this surgical method. Analysis was done using 2 × 2 contingency tables applying the Yates chi-square test, Fischer's exact test and Kaplan Meier survival probability method. All the descriptors for all data are given the median and range.

Results

Amongst the 32 patients were 27 men and 5 women. Median age was 47 years (range: 25—66). All patients had a history of at least had one episode of DVT verified by ultrasound or venography. The median time elapsed after the first DVT episode was 16.3 years (range 1.5—35). The following conditions were identified as possible trigger factors for DVT:

a) Thrombophilia (14), b) surgery/trauma (7), c) spontaneous/unknown (7), d) post-partum (3) and d) inflammatory bowel disease (1). Fourteen patients (44%) had an inherited thrombophilia (Table 1). In 9/14 patients this diagnosis was not established until they consulted our vein clinic. Prior to VVR, 22/32 patients were operated on to abolish superficial vein (18), perforator (1) and combined (3) reflux.

All patients had deep reflux in the popliteal and crural veins levels shown by CDU. Descending video-venography showed nine cases with reflux grade III and 23 with grade IV according to Kistner's classification.[17] High levels of AVP were recorded in all clinical groups (Table 2).

Table 2 CEAP classification and ambulatory venous pressure levels of the 32 patients in this series (values are the median and range)

CEAP groups		
C	N	AVP mm Hg
C4	2	93 (76—110)
C5	11	80 (60—90)
C6	19	88 (68—125)

Forty-three procedures were performed in 32 patients. Twenty-one patients received single procedures and 11 patients multiple procedures (all multilevel). Several different techniques were used, but in the majority of cases a venous valve auto-transplant was performed (32/43). External venous valve plasty and venous transposition were combined with transplant and/or used alone (Table 3a and b).

At three months follow-up 26/32 (81%) patients had competent valve plasties. Four patients presented with incompetent transplanted valves which were regarded as failures, and two patients with thrombosed single transplants. Clinical success (defined as symptom relief and/or ulcer healing) was accomplished in 25/32 (78%) Table 4. Ulcer healing was accomplished in 13/19 patients (68%), and other 12 patients had symptom relief.

Haemodynamic improvement (post-op. AVP reduction ≥20 mm Hg) was observed in 10 patients. All patients with haemodynamic improvement obtained clinical success but not all with clinical success experienced haemodynamic improvement (Table 5).

In 8/13 (54%) patients who healed an ulcer post-operatively, a median post-operative AVP reduction of 33 mm Hg (range 20—38) was observed. In patients with

Table 3 a and b. Type of surgery performed in each patient and at which level. Figures are the number of patients

Single Repairs - Single Level			
	External Plasty	Transplantation	Transposition
Femoral	2	3	1
Popliteal	1	14	

Multiple Repairs — Multiple Level				
	Multi External Plasty	Double Transplantation	External Plasty + Transplantation	Transposition + Transplantation
Fem + Pop	2	3	1	1

Table 4 Clinical success after VVR over the follow-up period

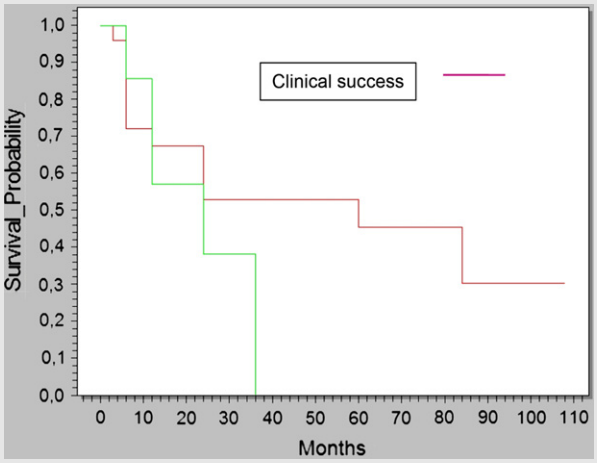

Table 6 AVP reduction and popliteal reconstruction together lead to longer ulcer-free period

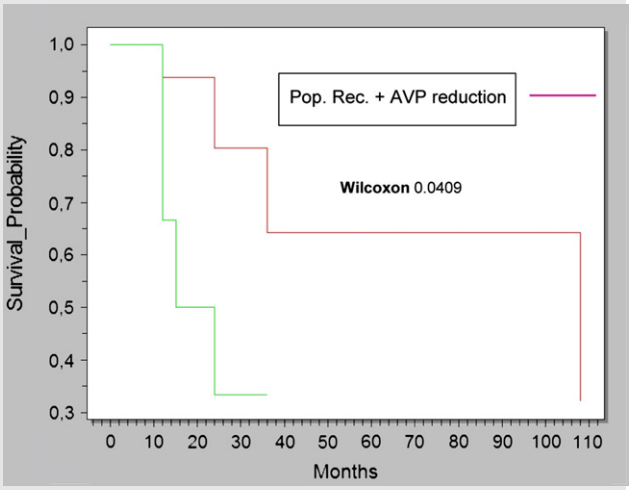

haemodynamic improvement ($n = 10$) the repair had a - median durability of 24 months (range 12—108), while in those *without* haemodynamic improvement ($n = 22$) the median durability was 18 months (range 6—108). This difference was not statistically significant.

A popliteal reconstruction had been performed in all patients (10/10) with haemodynamic improvement, and in 14/22 without. VVR at the popliteal level alone or combined with inguinal reconstruction was found to be the one significant factor associated with haemodynamic improvement ($p = 0.014$, Chi squared). Durability of VVR was longer in those with a popliteal reconstruction, median 24 months (6—108) when compared to those without it, median 6 months (6—84). Popliteal reconstruction and haemodynamic improvement together provided the best durability and the longer recurrence-free period (Table 6). Multiple-repairs ($n = 11$) seemed to have a greater numerical durability, although this did not reach statistical significance.

Among those with clinical success 13 patients (C5-C6) had an ulcer-free and symptom-free period of median 36 (range 6—108) months and have not yet reached an endpoint. The two patients in the C4 group had a symptom-free period of 12 and 36 months, respectively. In the C5 group 7/9 reached endpoint after a median recurrence-free period of 24 (range 6—84) months. And in the C6 group 5/13 reached endpoint after an ulcer-free period of median 12 (range 6—24) months.

Table 7 illustrates the durability and clinical success rate in the follow-up period, 47% and 40% after 3 and 7 years, respectively.

Three of the six auto-transplants from the axillary vein became incompetent within 6 months, while the other three have been competent a median of 108 (range 72—108) months.

Of the 26 auto-transplants from saphenous veins 12 were incompetent after a median of 24 (6—60) months and 14 had a competent period of median 30 (6—72) months.

Table 5 Number of patients experiencing clinical success (symptom relief and/or ulcer healing) related to haemodynamic improvement (Post op. AVP reduction of ≥20 mm Hg) in the different CEAP groups

C	N	Clinical success	Haemodynamic improvement
C4	2	2	2
C5	11	9	1
C6	19	14	7
Total	32	25	10

Discussion

Detailed knowledge of the underlying venous pathophysiology is mandatory in planning effective treatment in patients with SCVI. One should be acquainted with the

Table 7 Venous Valve Reconstruction (VVR) competence and clinical success in the follow-up period

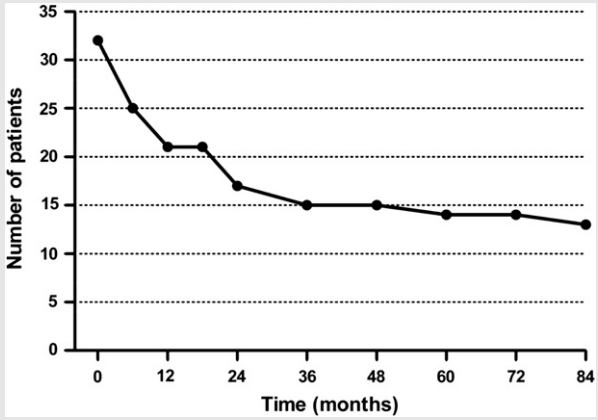

various VVR techniques and how to combine them to achieve the best haemodynamic results. Auto-transplantation was, by far, the most commonly used procedure (32/43) in this series of VVR in SCVI patients. We introduced our choice of in-lay technique to interpose the vein segment containing a competent valve, where the native vein is wrapped around as a reinforcing cuff without compromising the valve function.

Clinical success seemed to be directly related to the competence of VVR. Haemodynamic improvement assessed by AVP reduction is associated with ulcer healing.

Reconstructing the popliteal level appears to be a key factor ($p = 0.014$) in accomplishing haemodynamic improvement. Popliteal reconstruction and haemodynamic improvement combined, provided the best durability and the longer recurrence-free period in these group of patients. Regardless the clinical stage it would appear that the durability of the reconstruction stabilizes around 24 months as seen in Table 6. Our long term results compare favourably to those reported in the literature by Kistner *et al.*[12] but are inferior to those of Raju's.[10] We were unable to prove that a saphenous vein is a better donor than the axillary vein, but have at least demonstrated that saphenous veins can actually be used effectively.

Testing for clotting factor abnormalities should be a part of the evaluation of these post-thrombotic patients since nearly 40% of our cases had a thrombophilia.

In the present study the performance of VVR in a selected group of patients led to ulcer-free periods with a reduced ulcer recurrence rate. Considering that these are patients who have not responded to other more conservative forms of treatment underscores the value of our results and the opportunity to improve their quality of life. In addition, according to Tennvall,[18] 101 euros can be saved in healthcare resources for each week a venous ulcer remains healed. These savings together with a reduction in sickness-leave are socio-economical benefits suggested by the durability in our results. Hopefully this positive experience will encourage the allocation of more resources and medical attention to deal with this rather neglected secondary form of CVI.

References

1 Coiteux I, Mazzolai L. Deep vein thrombosis: epidemiology, risk factors and natural history. *Schweiz Rundsch Med Prax* 2006; **95**(12):455—9.

2 Roumen-Klappe EM, den HM, Janssen MC, van d V, Thien T, Wollersheim H. The post-thrombotic syndrome: incidence and prognostic value of non-invasive venous examinations in a six-year follow-up study. *Thromb Haemost* 2005;**94**(4):825—30.

3 Kahn SR, Ginsberg JS. The post-thrombotic syndrome: current knowledge, controversies, and directions for future research. *Blood Rev* 2002;**16**(3):155—65.

4 Leizorovicz A. Long-term consequences of deep vein thrombosis. *Haemostasis* 1998;**28**(Suppl. 3):1—7.

5 Bradbury AW, MacKenzie RK, Burns P, Fegan C. Thrombophilia and chronic venous ulceration. *Eur J Vasc Endovasc Surg* 2002; **24**(2):97—104.

6 MacKenzie RK, Ludlam CA, Ruckley CV, Allan PL, Burns P, Bradbury AW. The prevalence of thrombophilia in patients with chronic venous leg ulceration. *J Vasc Surg* 2002;**35**(4): 718—22.

7 Vowden KR, Vowden P. Preventing venous ulcer recurrence: a review. *Int Wound J* 2006;**3**(1):11—21.

8 Ruckley CV, Callam MJ, Harper DR, Dale JJ, Gibson B, Prescott RJ. Randomized clinical trial comparing the efficacy of two bandaging regimens in the treatment of venous leg ulcers (Br J Surg 2002; 89: 40—4). Letter 1. *Br J Surg* 2002;**89**(6):810.

9 Nelson EA, Harper DR, Prescott RJ, Gibson B, Brown D, Ruckley CV. Prevention of recurrence of venous ulceration: randomized controlled trial of class 2 and class 3 elastic compression. *J Vasc Surg* 2006;**44**(4):803—8.

10 Raju S, Fredericks RK, Neglen PN, Bass JD. Durability of venous valve reconstruction techniques for ''primary'' and postthrombotic reflux. *J Vasc Surg* 1996;**23**(2):357—66.

11 Kistner RL, Eklof B, Masuda EM. Deep venous valve reconstruction. *Cardiovasc Surg* 1995;**3**(2):129—40.

12 Masuda EM, Kistner RL. Long-term results of venous valve reconstruction: a four- to twenty-one-year follow-up. *J Vasc Surg* 1994;**19**(3):391—403.

13 Neglen P, Raju S. Detection of outflow obstruction in chronic venous insufficiency. *J Vasc Surg* 1993;**17**(3):583—9.

14 Kistner RL, Eklof B, Masuda EM. Diagnosis of chronic venous disease of the lower extremities: the ''CEAP'' classification. *Mayo Clin Proc* 1996;**71**(4):338—45.

15 Kistner RL, Ferris EB, Randhawa G, Kamida C. A method of performing descending venography. *J Vasc Surg* 1986;**4**(5):464—8.

16 Rosales A, Slagsvold CE, Kroese AJ, Stranden E, Risum O, Jorgensen JJ. External Venous Valve Plasty (EVVP) in Patients with Primary Chronic Venous Insufficiency (PCVI). *Eur J Vasc Endovasc Surg* 2006;**32**(5):570—6.

17 Masuda EM, Kistner RL. Prospective comparison of duplex scanning and descending venography in the assessment of venous insufficiency. *Am J Surg* 1992;**164**(3):254—9.

18 Tennvall GR, Andersson K, Bjellerup M, Hjelmgren J, Oien R. Treatment of venous leg ulcers can be better and cheaper. Annual costs calculation based on an inquiry study. *Lakartidningen* 2004;**101**(17):1506—13.